Oral Pathology
Biopsy

Ass. Prof. Dr. Afrah Adnan Aldelaimi
B.D.S., C.D.I., M.Sc., Ph.D.
Oral & Maxillofacial Pathologist
University of Anbar - College of Dentistry

Oral and maxillofacial pathology
is the specialty of dentistry and a branch of pathology that addresses the identification, nature and management of diseases affecting the oral and maxillofacial regions.

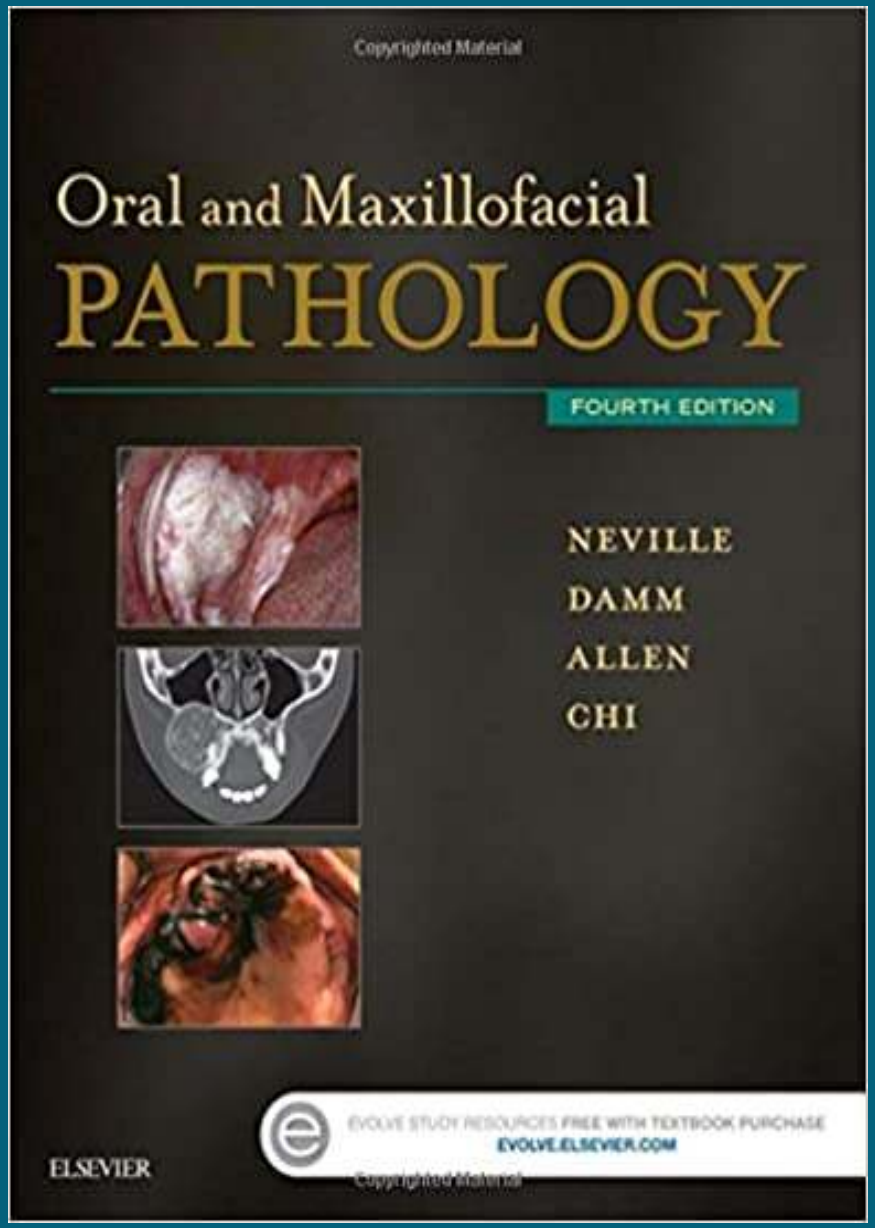

Surgical Pathology

is that specialty of pathology which deals with the diagnosis of diseases by microscopical examination of tissues taking by a surgeon ((Biopsy)).

Biopsy may be defined as removal of tissue from a living organism for histopathological examination.

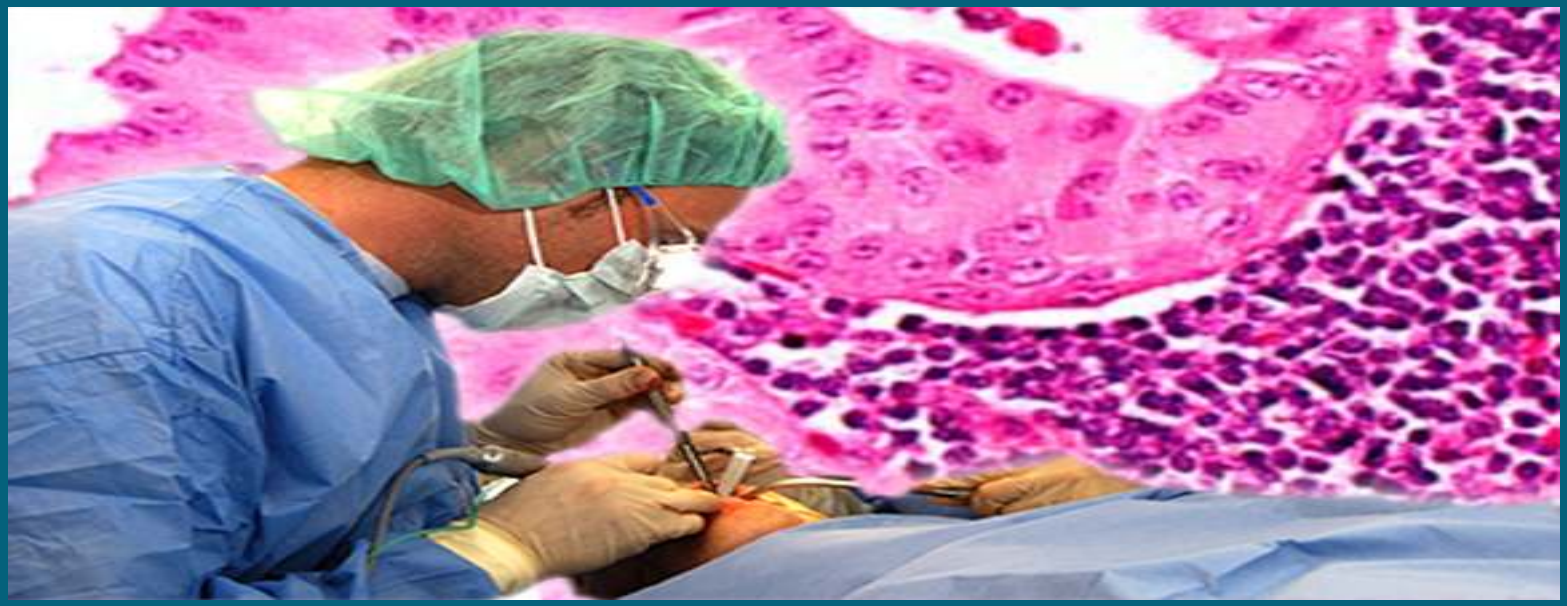

Types of biopsy according to the size of tissue:

Incisional biopsies & Excisional biopsy

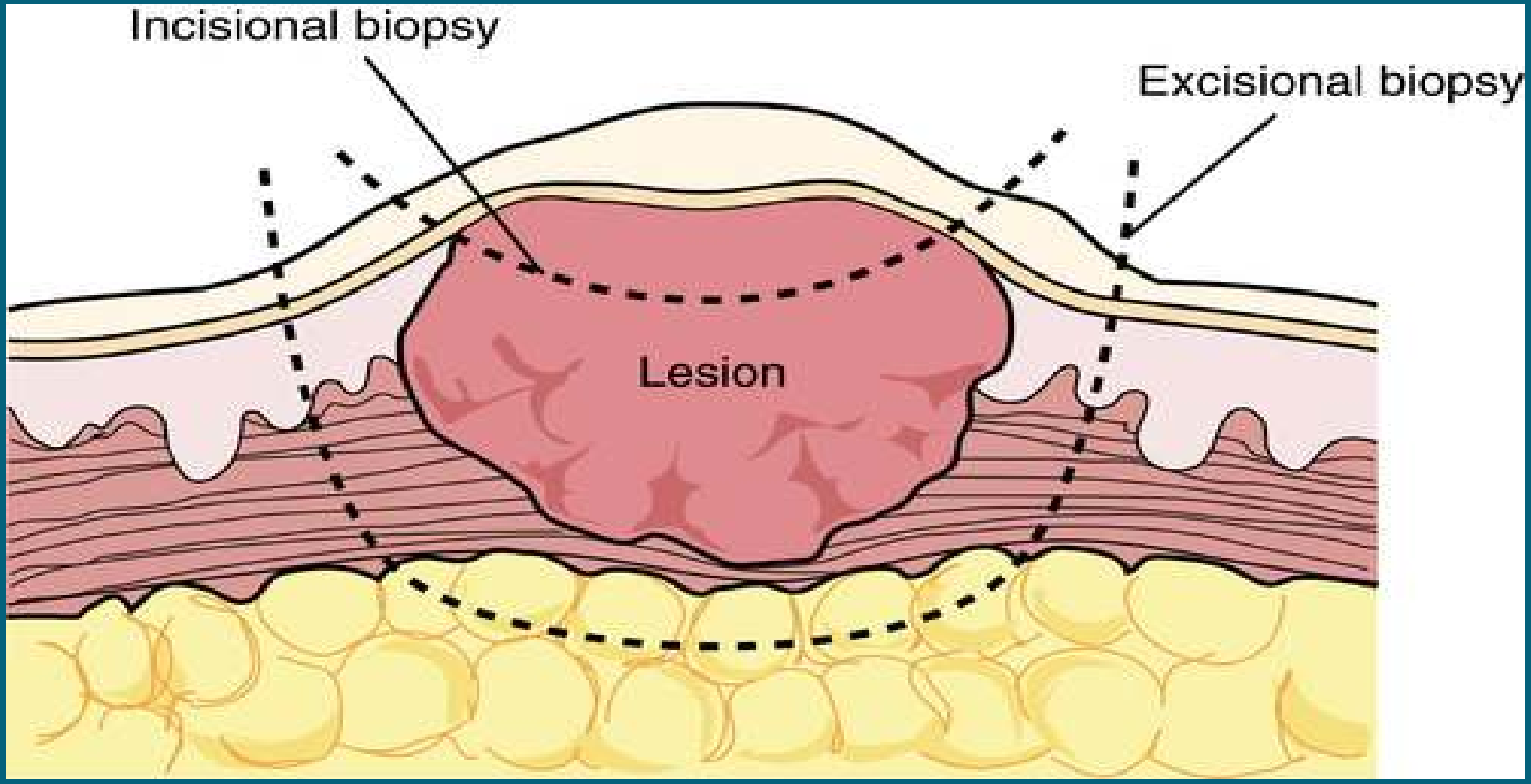

Excisional biopsy

It is indicated when the size of the pathological tissue is less than 2 cm and the surgical procedure can be performed at the dental clinic.

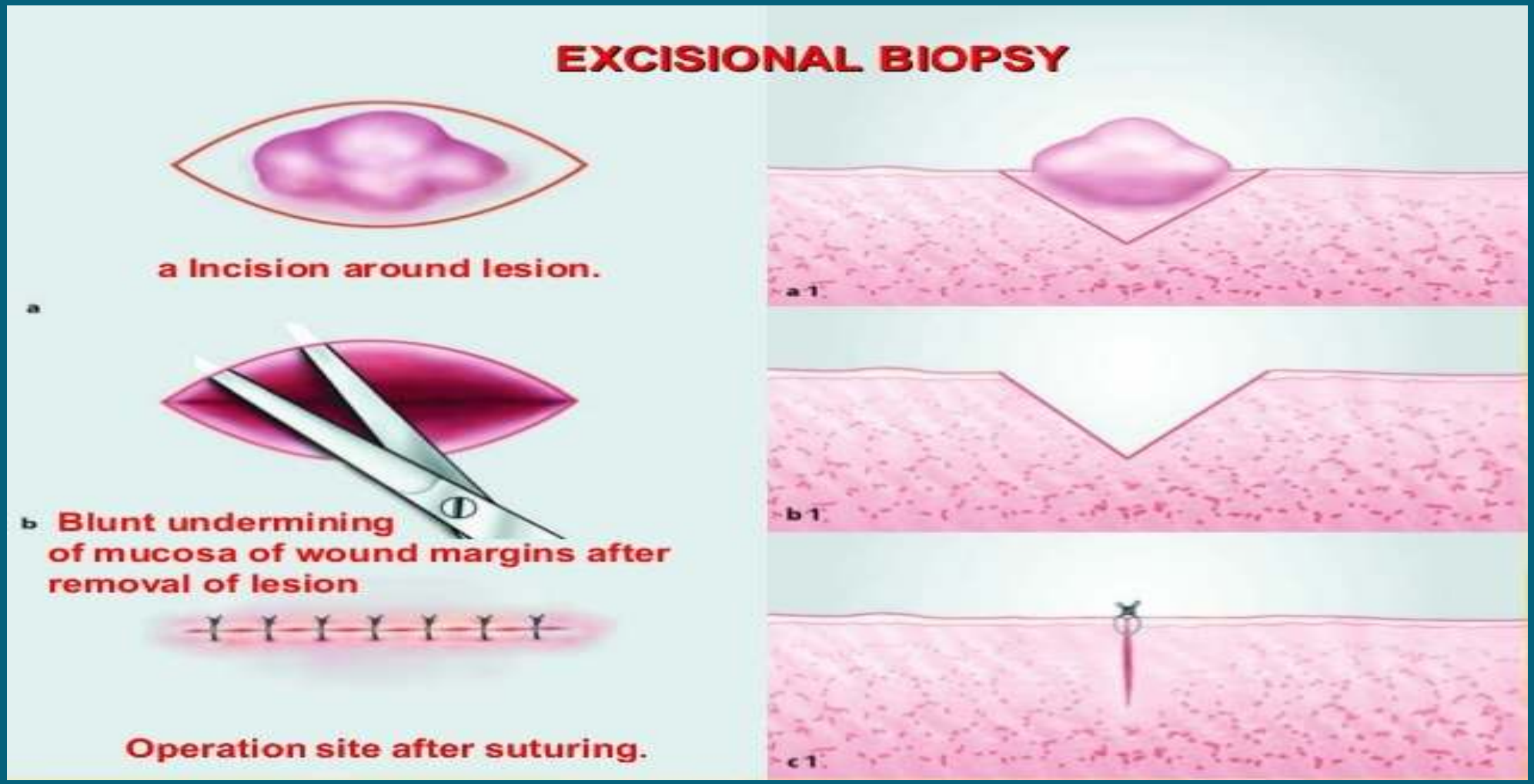

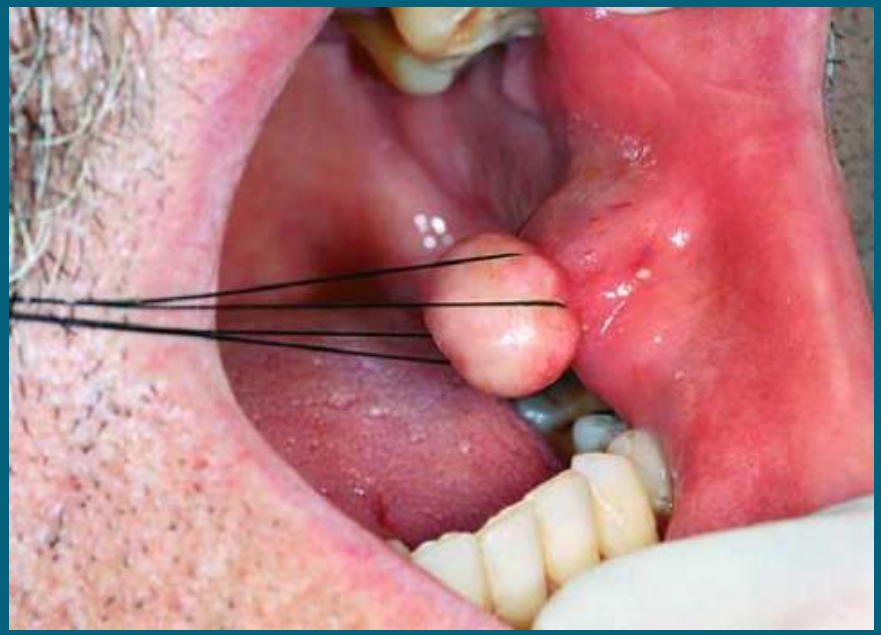

Incisional Biopsy or Wedge Biopsy

It is indicated when the size of the pathological tissue is more than 2 cm.

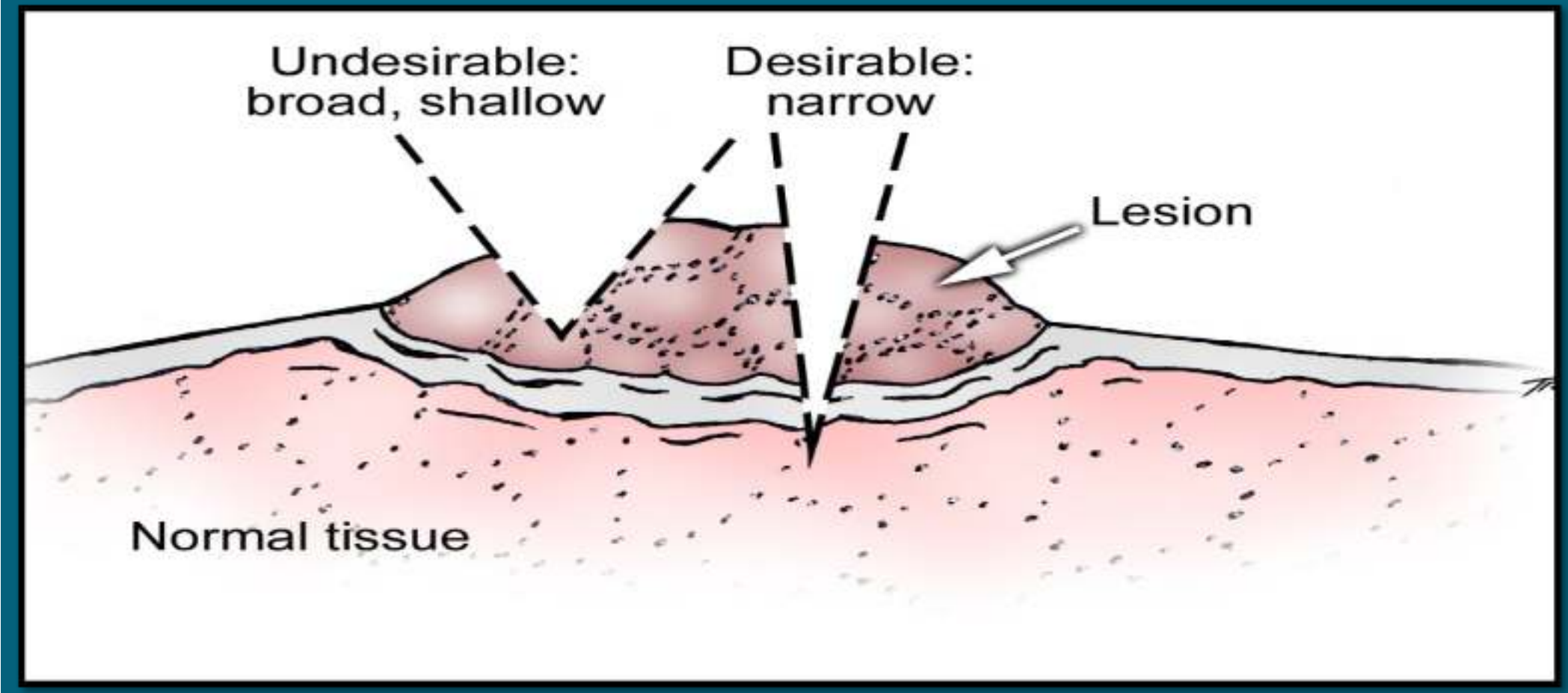

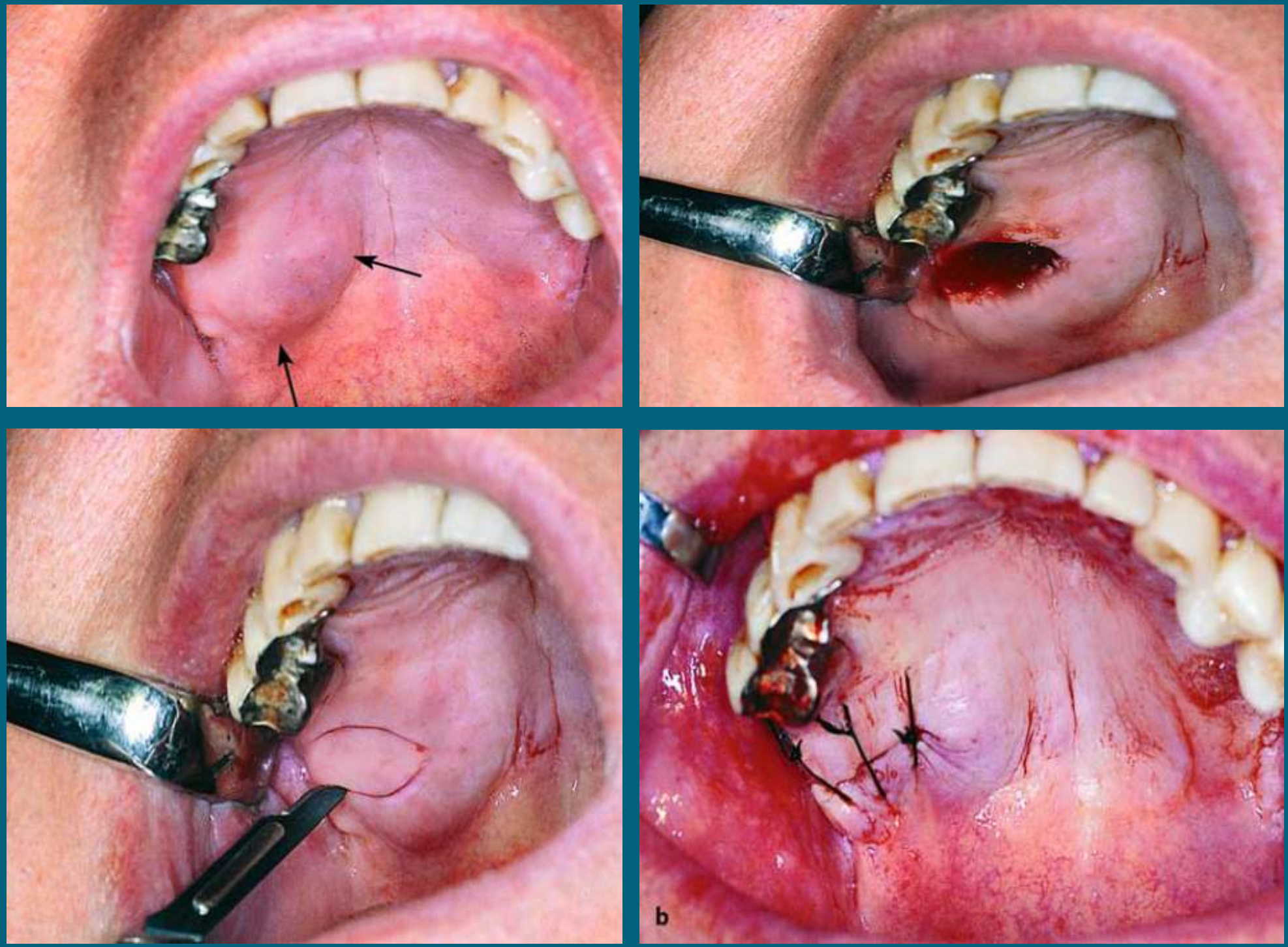
b

Types of biopsy according to the instruments used to obtain them

1-Cautery:

It is least suitable for microscopic examination because this instrument chars and distorts tissues.

2-Cone biopsy

it removes a cylindrical or cone shaped piece of tissue, it is performed to diagnose cervical cancer following a pap smear.

Colposcopy (examination of the cervix under illuminated magnification), and a punch biopsy.

3- Core needle biopsy: it is performed by inserting a small hollow needle through the skin and into the organ or abnormality to be investigated.

The needle designed with a cutting tip to help remove the sample of tissue and with the use of spring loaded gun to help remove the tissue sample

PRINCIPLE OF TRUCUT BIOPSY

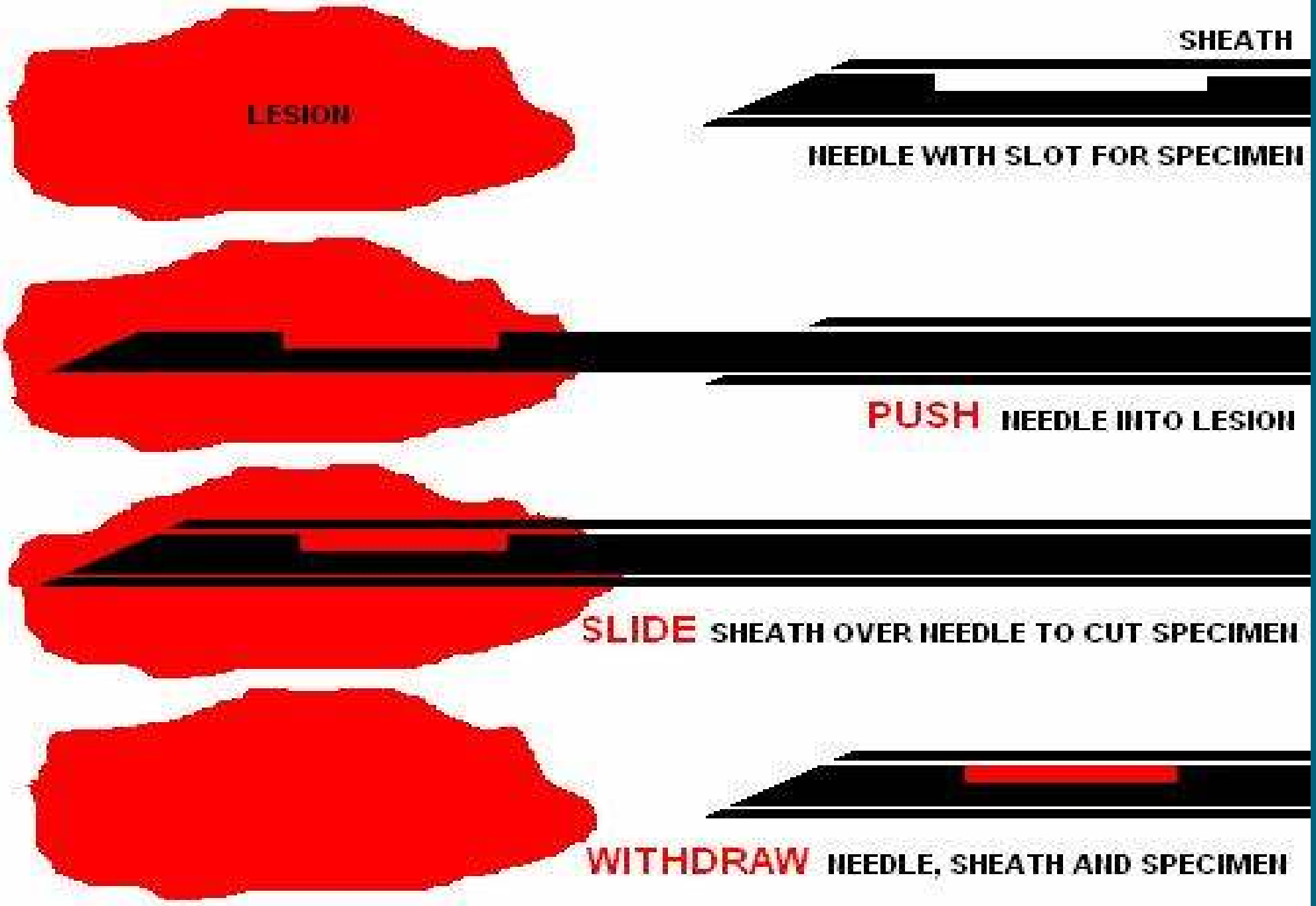

4-Vacuum Assisted Biopsy:

Core biopsy with a vacuum device to removal of multiple samples with only one needle insertion. Used in breast biopsy procedures

5-Endoscopic Biopsy: very common by using a fiber optic cable for viewing inside the body which is inserted into the b

6- Punch Biopsy: used by dermatologists to sample skin rashes, moles and other small masses. After a local anesthetic is injected.

Punch Biopsy Procedure

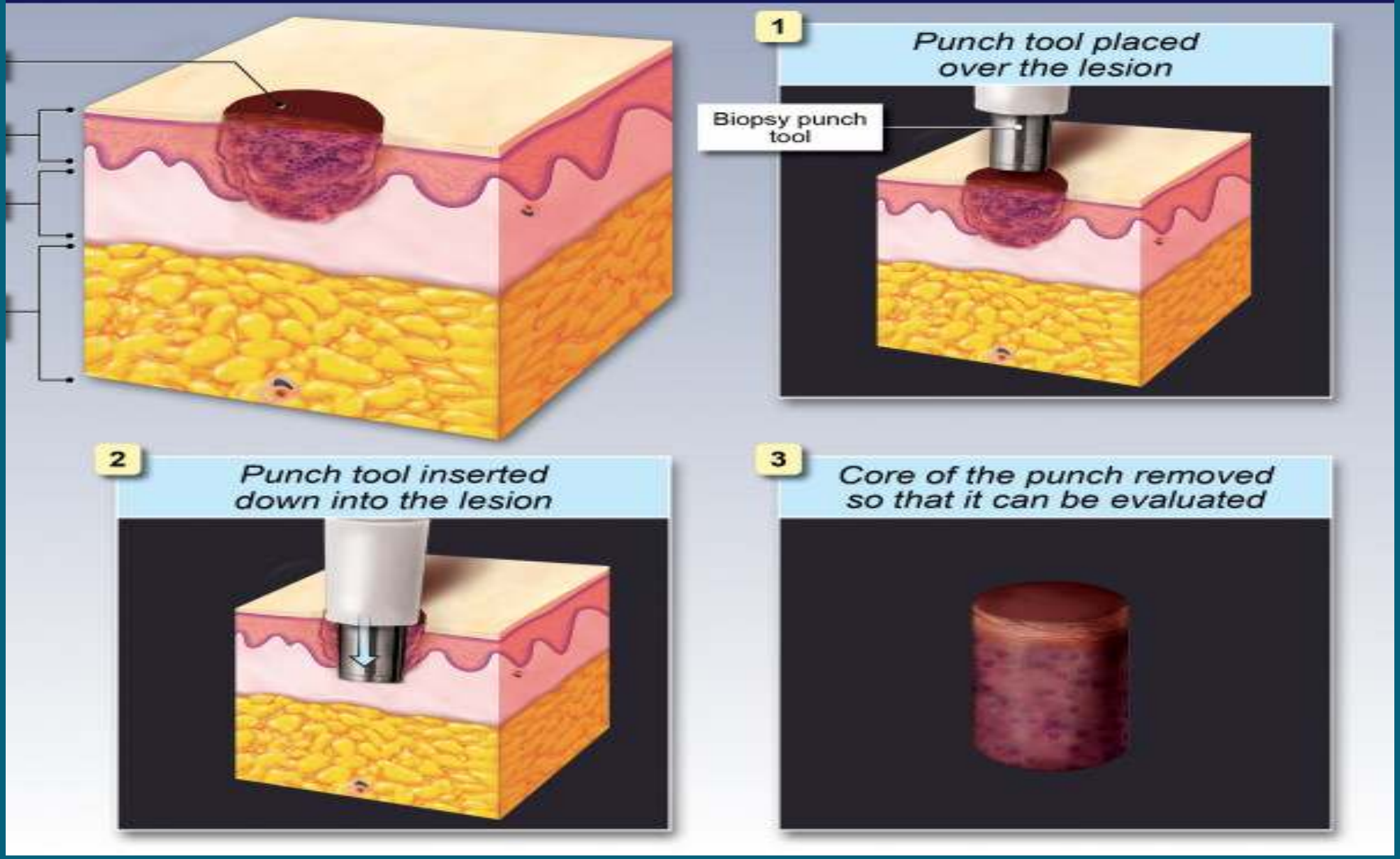

7- Surface Biopsy:

sampling or scraping the surface of a sore or tumor to remove cells for pathologic testing. Used by dermatologists to remove a small piece of skin to test for carcinoma.

Diagnostic cytology:

Study of cells to identify diseases. Many procedures to perform sample , but usually involve taking either a sample of body fluids or a scraping of cells from body tissue. Diagnostic cytology may be used to help identify various types of cancer and certain infections.

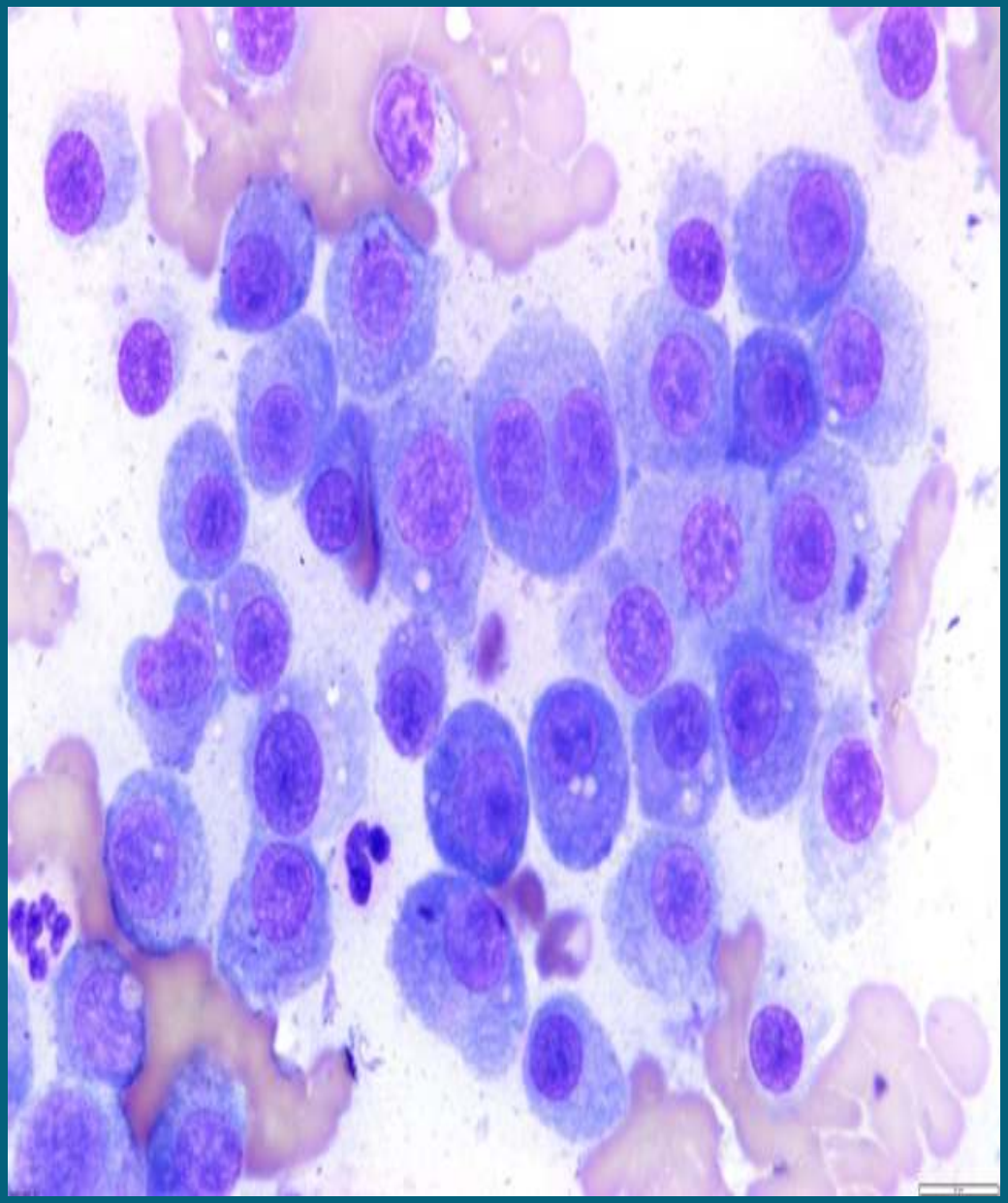

- Cytology is not a substitute the surgical biopsy.
- It is quick, simple, painless and bloodless procedure.
- It helps as a check against false – negative biopsies.
- It is helpful in follow-up and detection of recurrent carcinoma in previously treated cases.
- It is valuable for screening lesions that grossly biopsy is not warranted.

Brush Biopsy

full transepithelial tissue taken Advantages of brush biopsy

- Reduced chair side time
- Simple procedure which is easy to master
- Quick results

Fine Needle Aspiration Biopsy

Aspiration biopsy is inexpensive, quick and easily performed technique.
The complete trans-tumor sample is composed of cells, tissue, or fluid and is useful in diagnosis of fluctuant lesions, deep-seated submucosal lesions and metastasis in enlarged cervical lymph nodes

Indications for Biopsy

- Any lesion that persist for more than 2 weeks with no apparent etiologic basis.
- Any inflammatory lesion does not respond to local treatment after 10-14 days.
- Persistent hyperkeratotic changes.
- Persistent tumescence, visible or palpable beneath normal tissue.
- Lesion that interfere with local function.
- Bone lesions not identified by clinical and radiographic findings.
- Any lesion has the characteristics of malignancy.

Characteristics raise the suspicion of malignancy:

Erythroplasia or speckled red appearance
Ulceration
Duration
Growth rate
Bleeding.
Induration
Fixation

Contraindications for Biopsy

- Acute inflammatory conditions such as cellulitis
- Normal anatomical variations such as linea alba
- Patients with bleeding disorders
- Vascular lesions such as haemangioma
- Patients who are on anticoagulant therapy

Exfoliative Cytology

examined cells shed from body surfaces, such as the mucosa. Not been a very useful for diagnosis of oral cancer

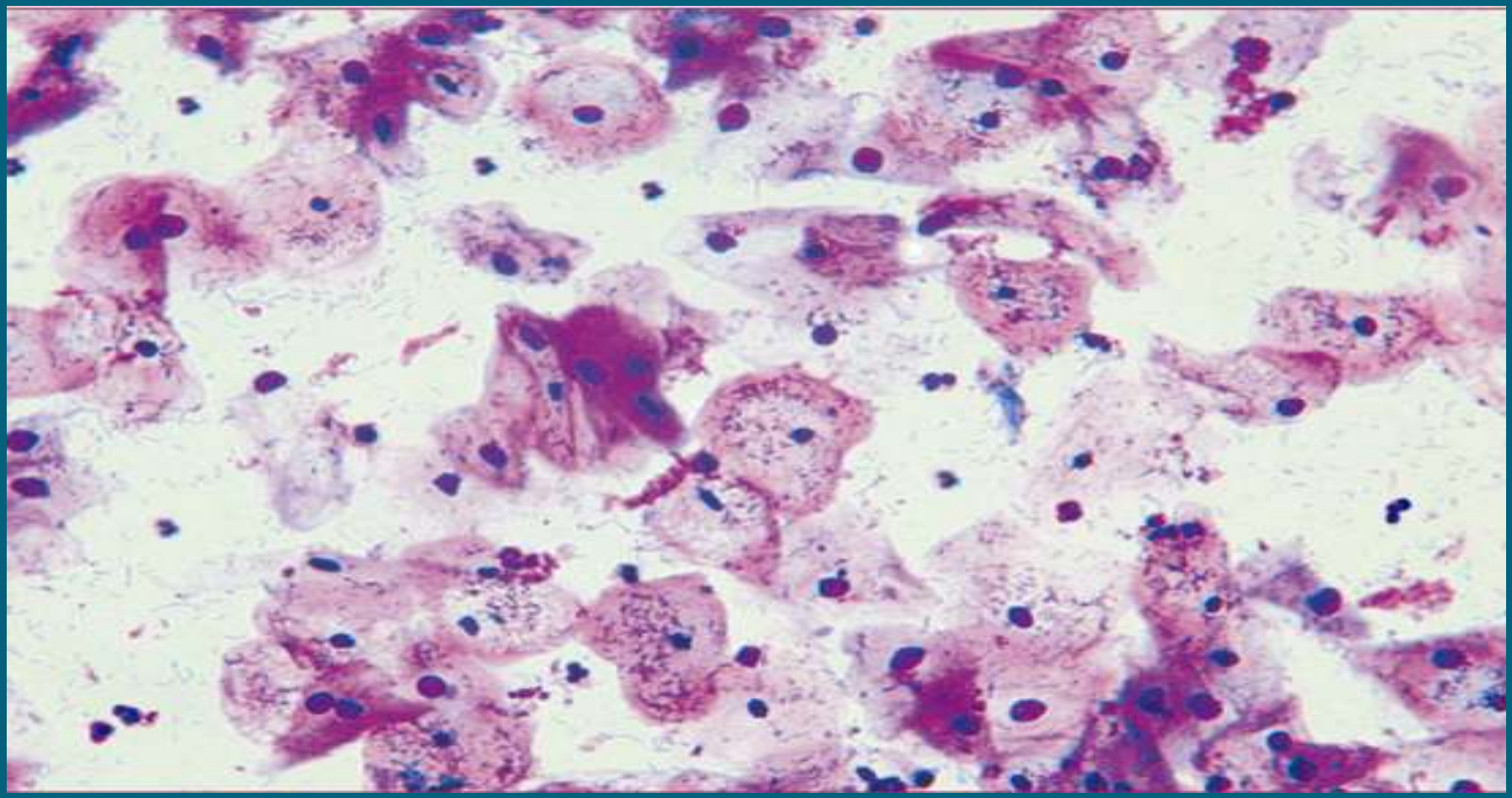

Laser Biopsy

It used for incisional and excisional biopsies and has advantages over the conventional scalpel:

1. Patient acceptance
2. There is little or no bleeding
3. Excellent visibility
4. Reduced operating time
5. Providing a relatively sterile operating field
6. There is little or no postoperative swelling due to sealing of blood vessels and lymphatics

Important principles to remember are the principles guidelines of biopsy and the principles of laser.

Principles of Biopsy Procedure

- It must be carried out as soon as possible.
- Choice of biopsy technique is determined by the indications of each case.
- Avoid inject local anesthetic solution inside the lesion causing distortion to the tissues.

- Used sharp scalpel to avoid tearing tissues.
- Stabilized mobile tissues (tongue, lip, soft palate, floor of mouth and buccal mucosa). The methods used to stabilize it are: finger stabilization, retraction suture, towel clips and retractors
- Avoid use of suction devices because you may lose your specimen in the suction.

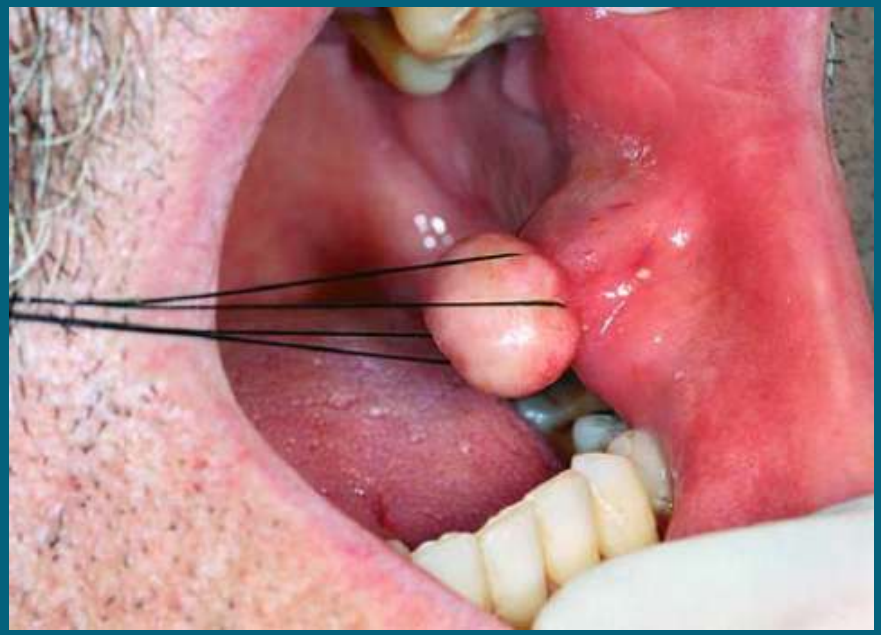

- Avoid using electrosurgical blade
- Avoid grasped with forceps
- The tissue specimen taken should be representative.
- Immediately placed the sample in a container with fixativeto avoid dryness.
- The fixative solution to be used is 10% formalin, and not water, alcohol, or other liquids that destroy the tissues

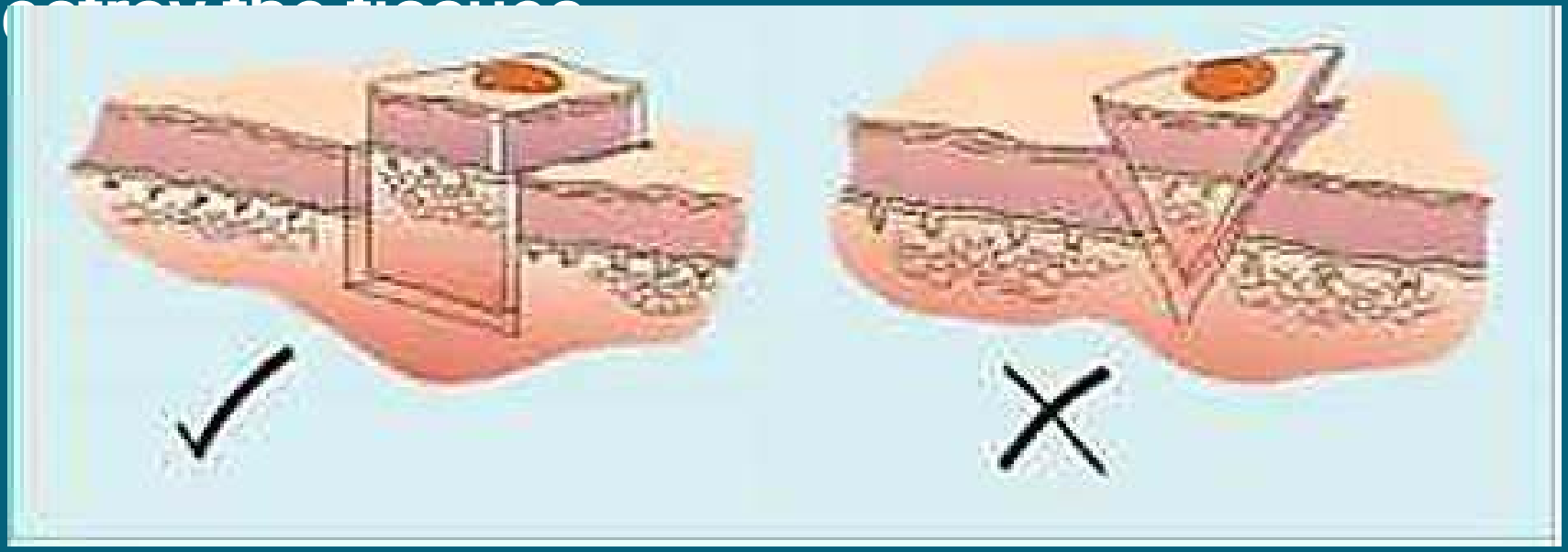

- The container prefer to be plastic to avoid risk of breakage during itransfer
- Labelled with the name of the patient and date should be placed on the side of the container and not on the lid.
- The larger the lesion, the more numerous the biopsies that should be taken.

- Avoid taken biopsy from the central area of ulcer
- If you want to put land marks on tissue use suture but don’t use iodine or highly colored antiseptic.
- During the biopsy procedure, consideration should be given to anatomical structures like neurovascular bundles that should be handled with care.

- A written consent from the patient prior to the biopsy procedure is very important, as there are risks involved in biopsy procedures such as paresthesia, and swelling.

Laboratory techniques in histopathology

1-Fixation: 10% buffered formalin remains the best one because

- Inexpensive
- tissue can remain in it for prolonged periods without deterioration
- compatible with most special stains

as long as the tissue is placed in fixative shortly (<30 min) after surgical removal, and overfixation (>24–48 hours) is avoided

Zenker fluid is an excellent fixative, one of the best that has ever been devised for light microscopic work, but it is expensive, requires careful disposal of the mercury.

Bouin fixative (which contains picric acid) has been especially recommended for testicular biopsies.

Bouin, Zenker, and B-5 are excellent fixatives for routine work and for most immunohistochemical stains, but the preservation of nucleic acids is very poor.

Laboratory tissue processing

It refers to any treatment of tissues necessary to impregnate them with a solid medium to facilitate the production of sections for microscopy.

1- Labeling of tissue

2- Completion of fixation process

3- Gentle and complete dehydration to remove aqueous fixative and any tissue water e.g. Ethanol and alcohol

4- Clearing with a substance which is totally miscible with both the dehydrating agent which precedes it and the embedding agent which follows it. e.g. Xylene

5- Embedding e.g. wax, resins and agar

we have two types of tissue processing. Manual and automated tissue processing

6- Microtomy-is the sectioning of tissue blocks by microtome

7- Staining either by ordinary stains (hematoxylin and eosin) or special stains

Periodic acid–Schiff (PAS) stain

This is an extremely useful and esthetically pleasing technique, and makes evident most types of fungi and parasites.

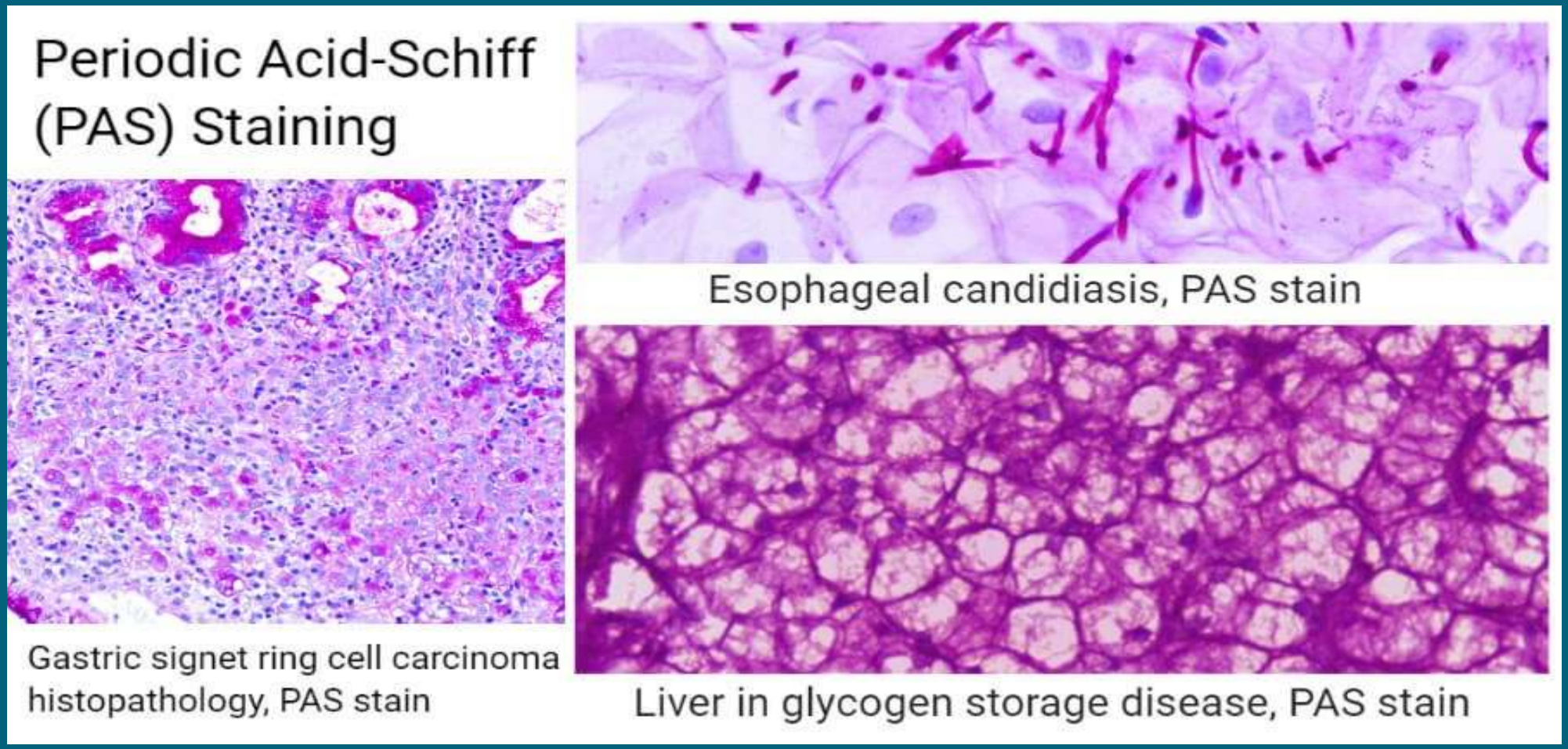

Stains for microorganisms

These include techniques for gram-positive and gram-negative bacteria, acid-fast mycobacteria, fungi, and parasites.

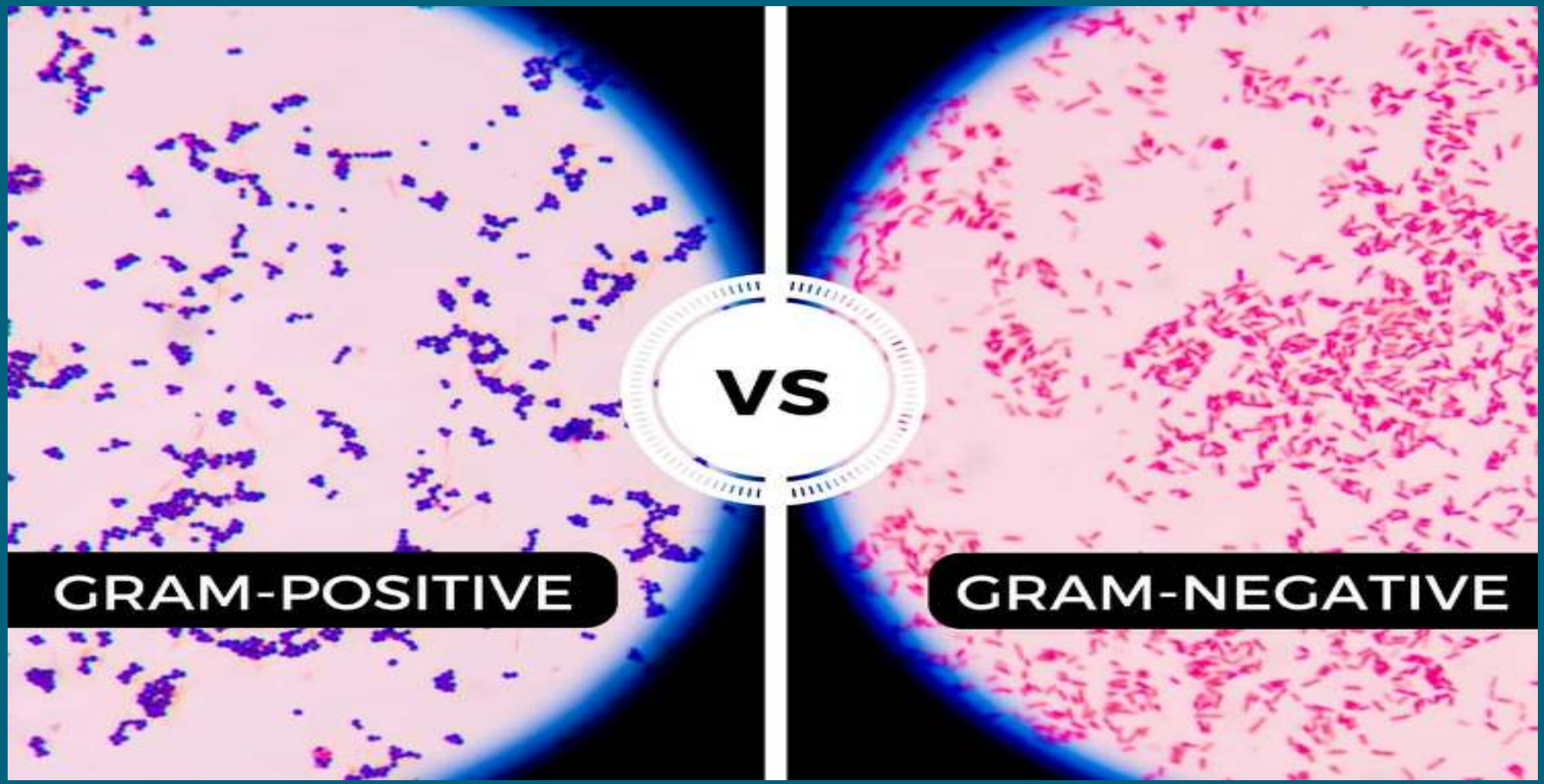

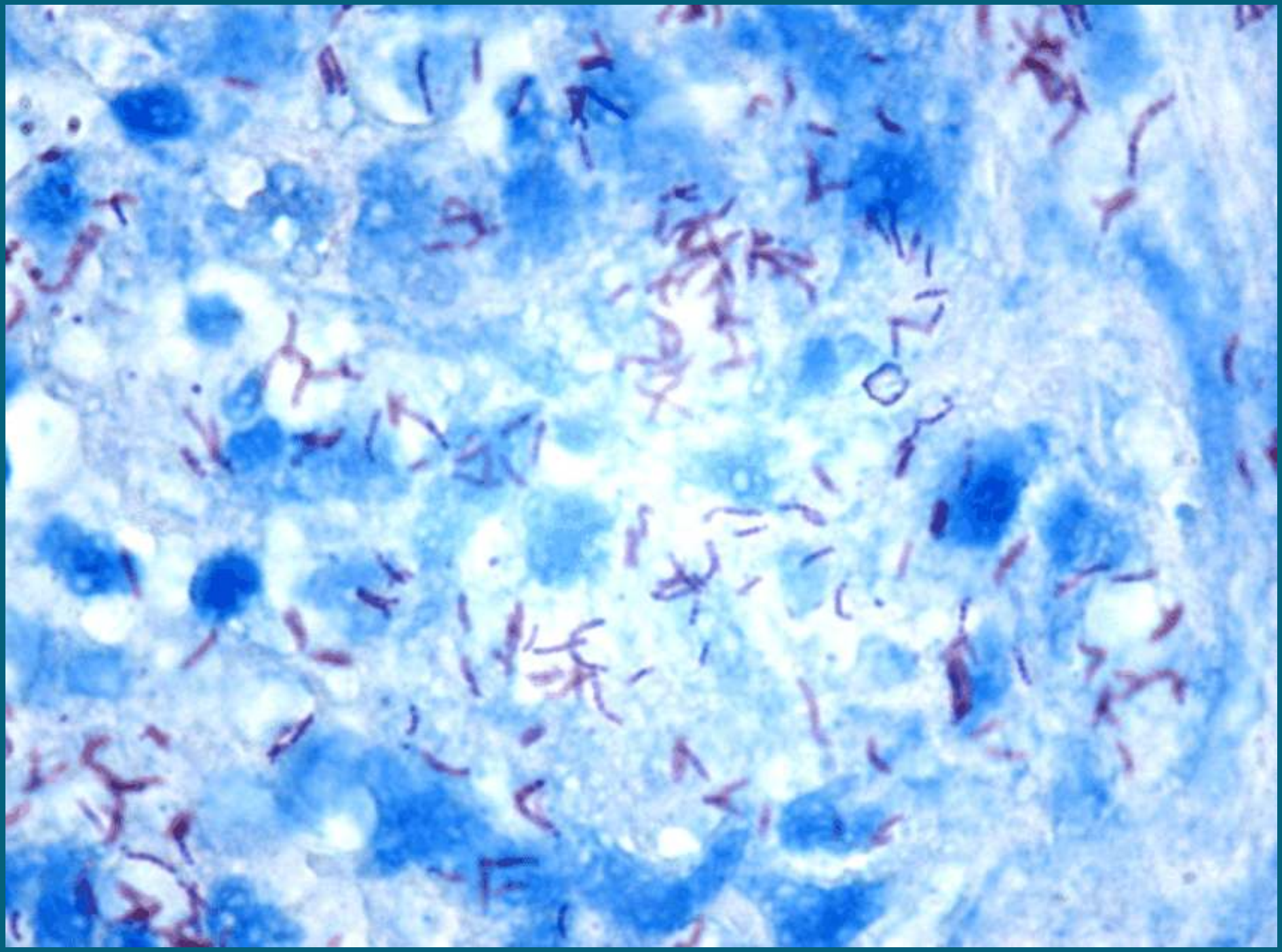

Argentaffin and argyrophilic stains

Silver stains are used for the identification of neuroendocrine cells and their tumors, but also for the demonstration of reticulin fibers, melanin, and calcium.

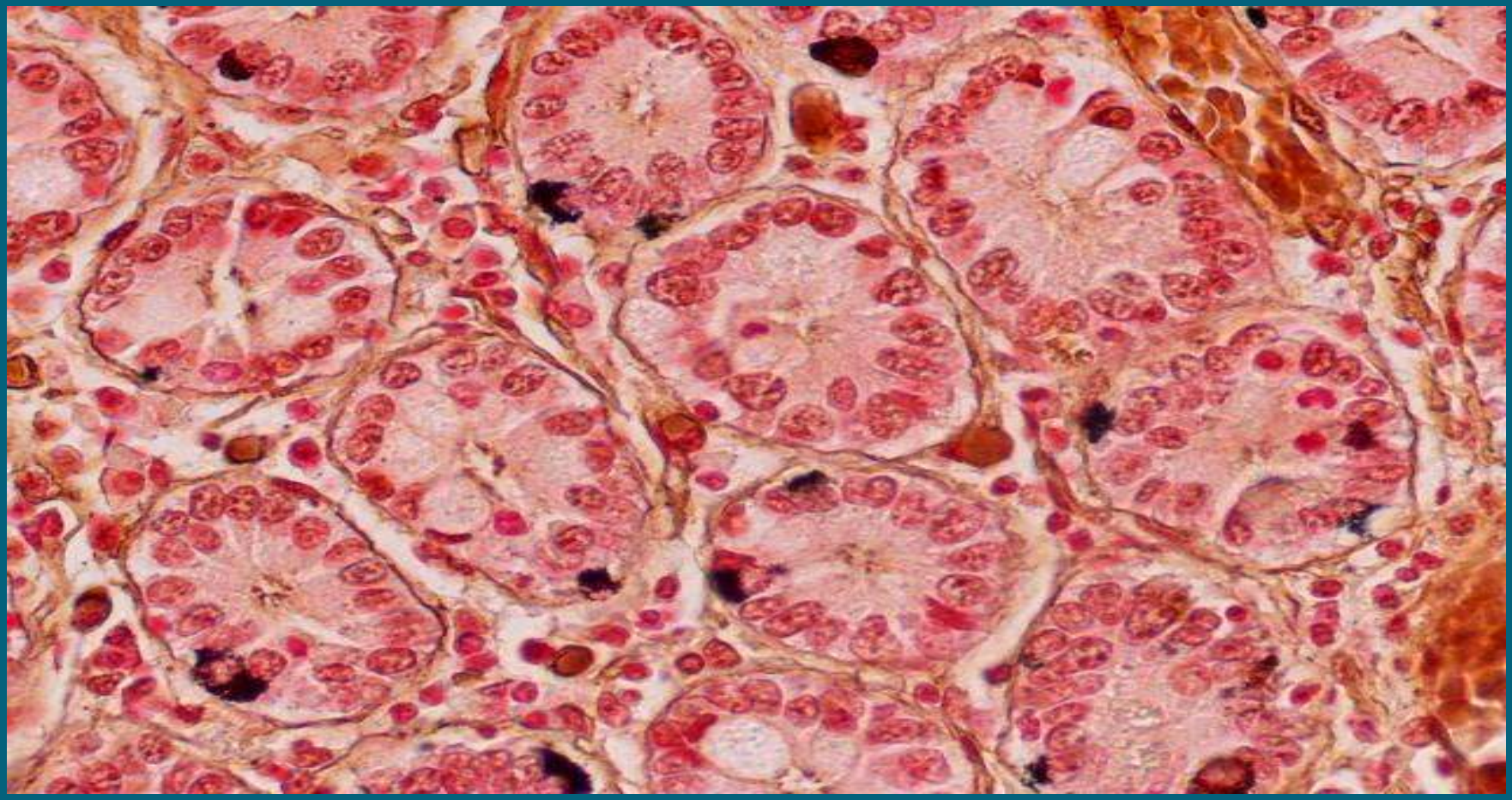

Amyloid stains

Congo red is regarded as the most reliable and practical technique to detect amyloid.

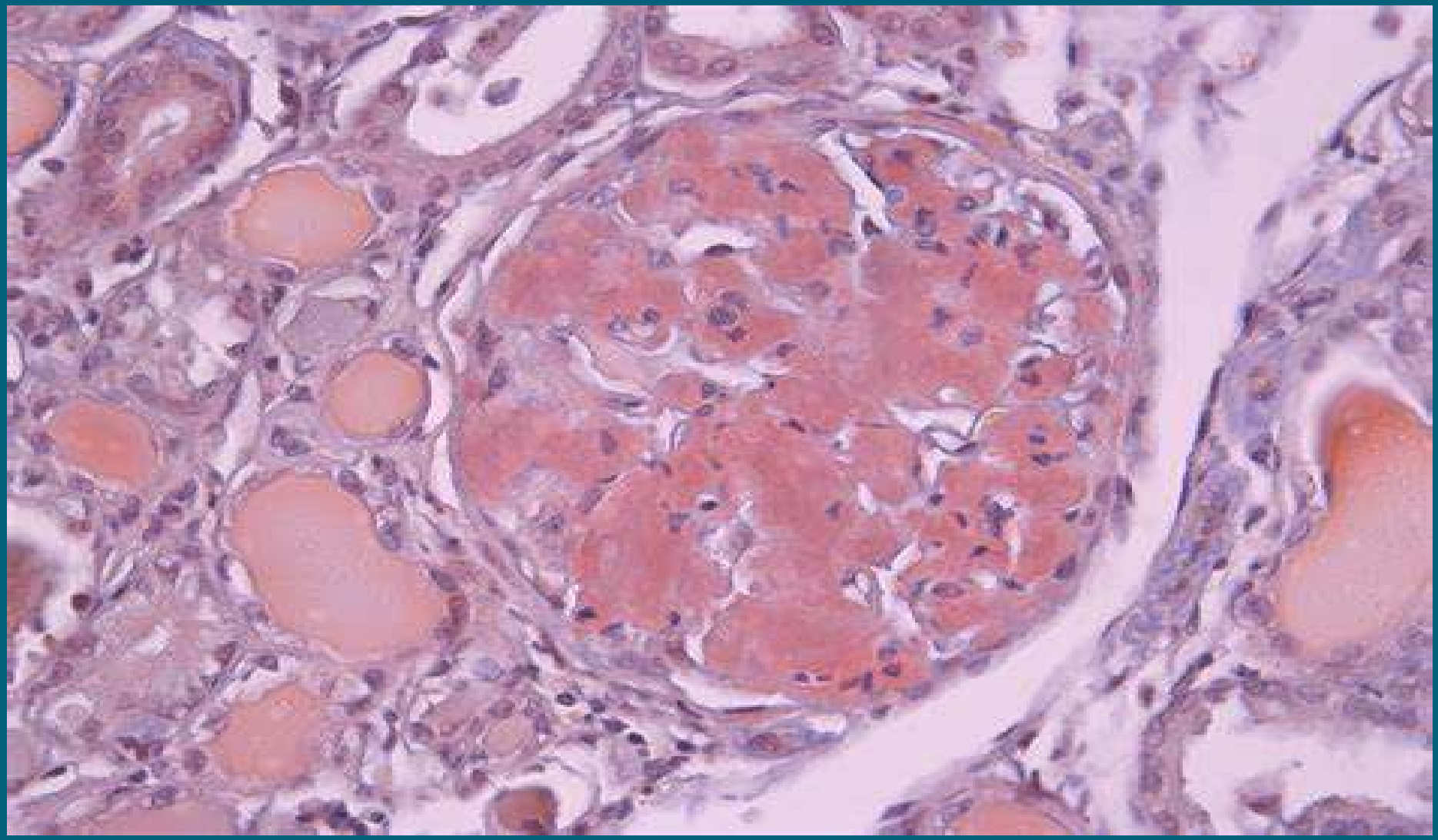

Reticulin stains

reticular fibers' and basement membrane material.

Trichrome stain

evaluation of the type and amount of extracellular material.

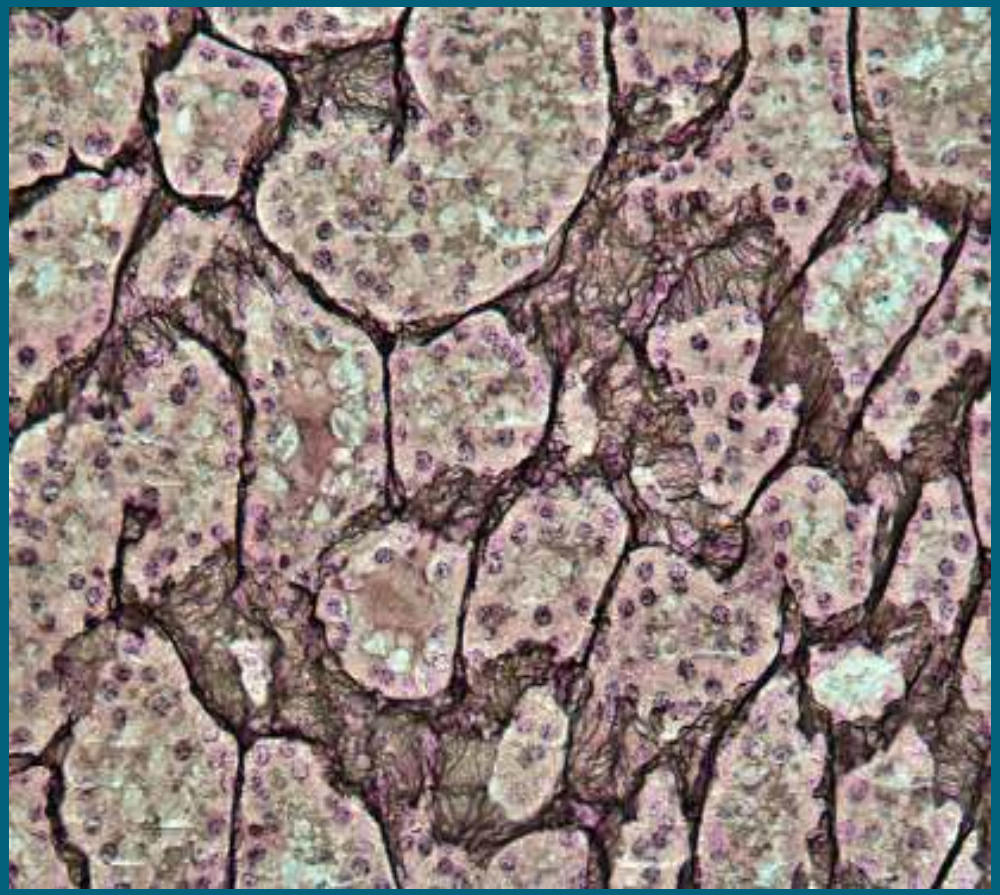

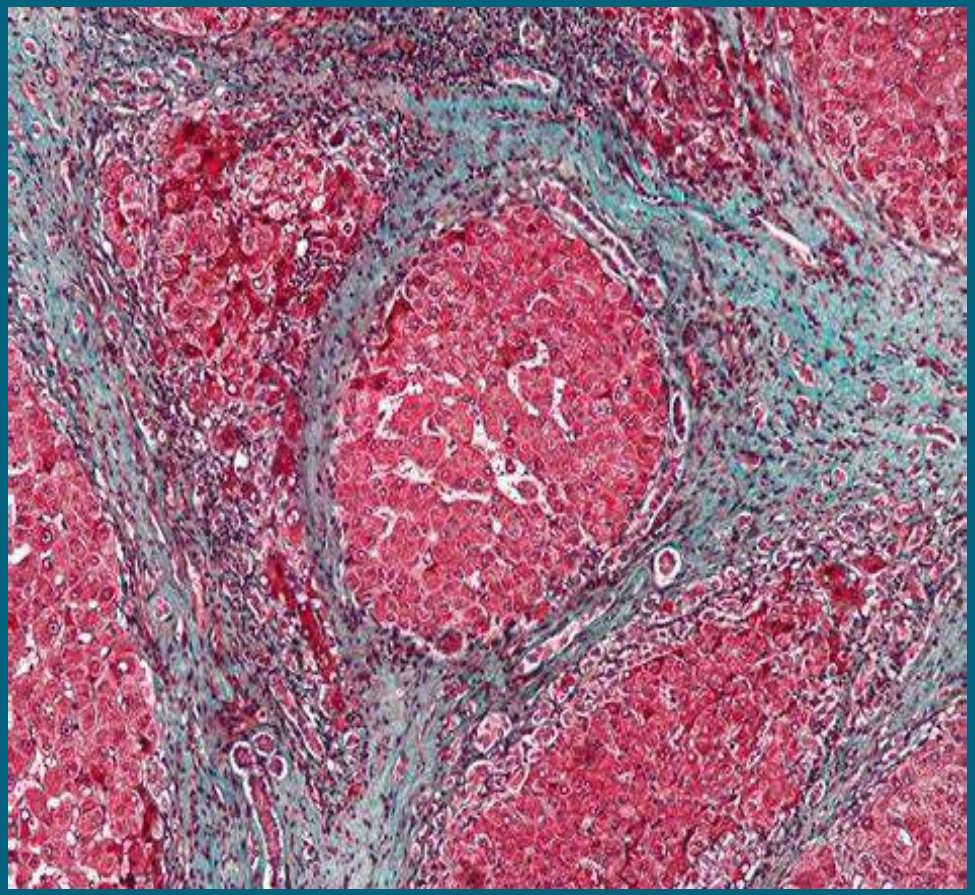

Phosphotungstic acid–hematoxylin (PTAH) stain

Stains for hemosiderin (Perls)

), and

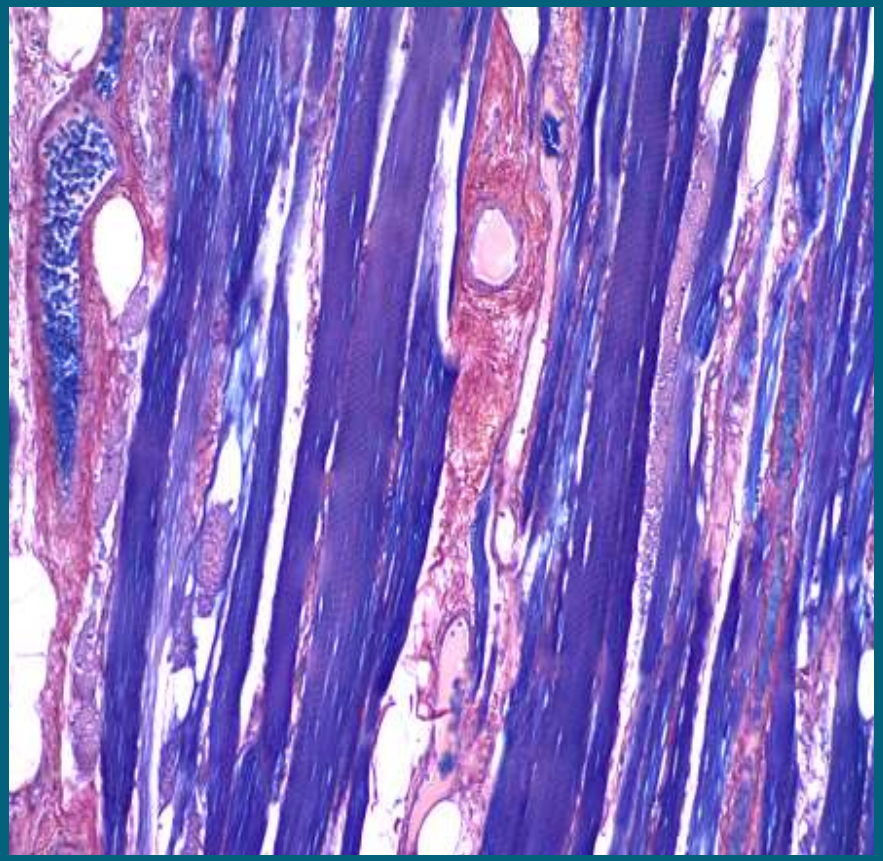

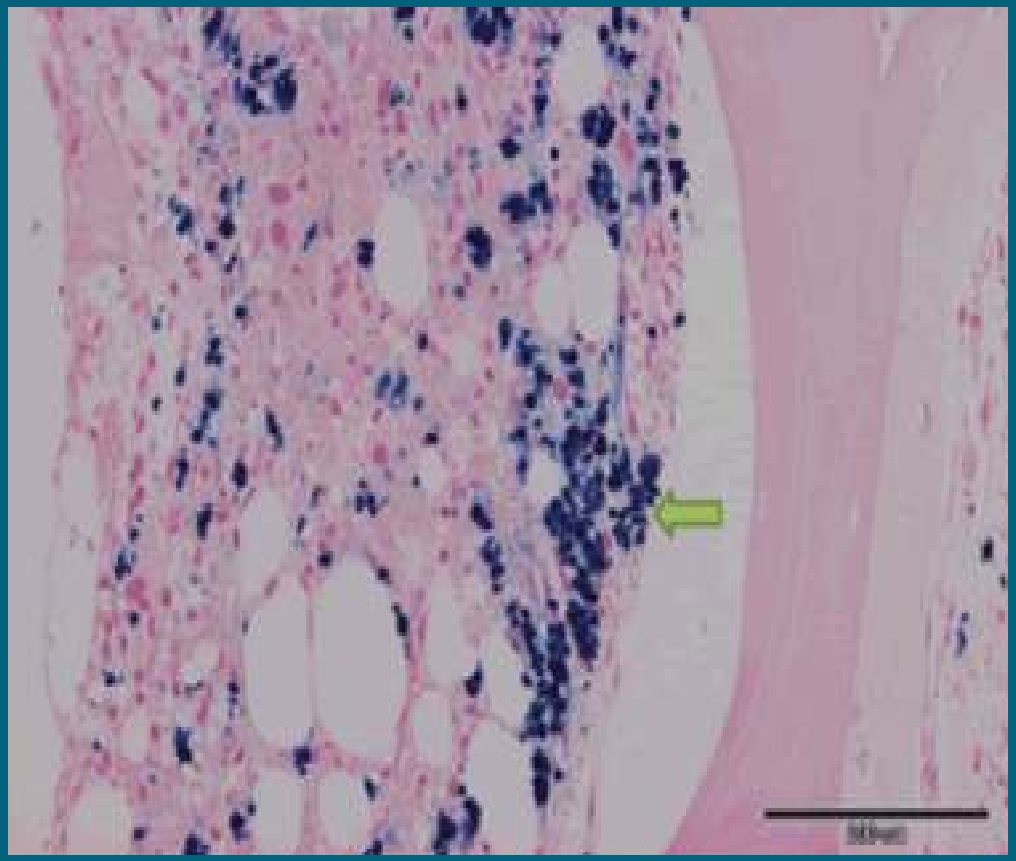

melanin (Fontana–Masson)

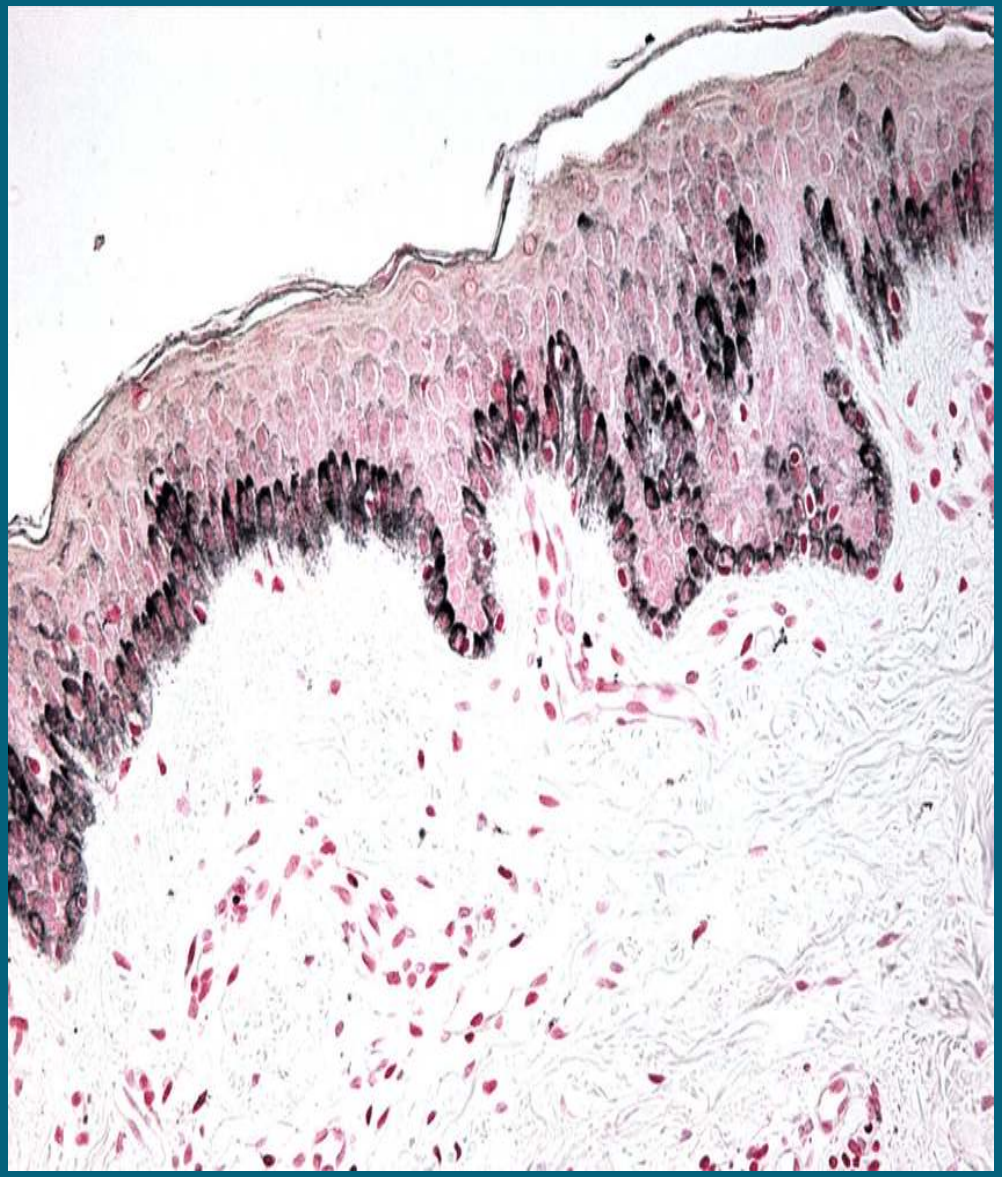

calcium (von Kossa).

Immunohistochemistry

It is the application of immunologic principles and techniques to demonstrate molecules in cells and tissues. The original method, brilliantly conceived by Coons, consisted of labeling with a fluorescent probe an antibody raised in rabbits and searching for it (and therefore for the antigen against which the antibody was directed) in tissue sections examined under a fluorescent microscope following incubation.

The most important diagnostic applications of immunohistochemical marker that have been applied widely to surgical pathology

Actin
Albumin,
P53
S-100 protein
Desmin.
CD34

Digital pathology and Telepathology

Capture digital images of gross and microscopic specimens which can be integrated with pathology reports. Telepathology is mean that uses telecommunications technology to facilitate the transfer of image-rich pathology data between distant locations for the purposes of diagnosis, education, and research.

Pathology report:

The usual pathological report is composed of five major fields:

Dermographic informations

Gross description

Microscopic finding

Diagnosis

Note or comment

Patient Name: TEST, TEST

Case #: D-08-0013911

DOB/Age/Sex: 11/6/1951 56 years Female

MRN: 99999

Collected: 02/5/2008 12:00:00 PM

Received: 02/5/2008 12:00:00 PM

Client Name: CLAREMORE INDIAN HOSPITAL

Provider: DOC TEST1 MD

Consulting:

Deliver to: N/A

N/A

N/A, N/A N/A

SURGICAL PATHOLOGY REPORT

Diagnosis

Skin, left axilla, punch biopsy-

axillary granular parakeratosis.

Test, Pathologist Pathologist (Electronic Signature)

PT 02/29/2008

Microscopic Examination

Sections show parakeratotic confluent scale containing an abundance of prominent keratohyalin granules. The underlying epidermis shows psoriasiform hyperplasia without acantholysis. The histology defines axillary granular parakeratosis.

Gross Examination

Punch biopsy of skin: left axillary

Size: 0.4 x 0.4 cm

Excision depth: 0.5 cm

Specimen is bisected and entirely submitted in 1 cassette for microscopic examination.

PT /PT

Specimen

From left axillary

Pertinent History

Hailey Hailey

THANK YOU